



## Analysis of box-tie related suspension nerve injuries

I have used the term box-tie to refer to takate-kote style ties, encompassing the arms and upper torso, used for suspension. The purpose of this document is to examine the construction methods and possible implications for the nerves likely to be affected. The first part will examine the classic style and the problems inherent. However, these hazards are not unique to this tie and the information is relevant to upper body bondage in general.

The second part, yet to be completed, will examine some of the common mistakes in attempting to execute this tie and the failures of some Western copies.

Whilst most injuries can be traced to inappropriate placement of ropes or poor construction, there still seem to be others which seem less explicable. I hope this document will be the basis from which to explore how accidents can be avoided or, even, if this type of tie or its usage can be improved.

### Part I: Traditional takate-kote

It appears that there is a classic consensus of form adopted by the Japanese shibari masters which, whilst differing slightly, has the same fundamental principals. These include:

1. Hands tied behind back with forearms parallel and arms bent at 90 degrees.
2. The simple form is typically based on two ropes, excluding the suspension rope/s
3. It comprises two parallel wraps, usually of two doubled bands of rope, one above the breasts and one below, encompassing the arms and torso. The upper wraps will normally be under greater tension than the lower wraps.
4. One or both wraps will be 'cinched' at the front only.
5. Some or all components will be 'locked off' to ensure that it is a separate

unit and does not tighten when other bindings are pulled.

6. Only the two parallel wraps, not the cinch ropes, to be included in the suspension rope/s.

In addition to the above, there may be some embellishment or further structural work depending on how much rope is left. Regardless, the above components comprise the basic form. Unfortunately, many Western approximations do not take all these considerations into account. Consequently, this can lead to increased risk. Hopefully, this document will alert people to the risks inherent in some non-standard or reverse engineered versions.

### Nerves of the upper body

There follows an illustrated discussion of the main nerves, and arteries which supply them, relevant to this tie and, indeed, bondage in general.

The following terms might be helpful in interpreting medical texts:

Anterior – The front side

Posterior – The rear side

Lateral – Away from the midline of the body

Medial – Towards the midline of the body

Proximal – Towards the centre of the body

Distal – Away from the centre of the body

Pronation – To rotate the arm inward so that the thumb points towards the body

Supination - To rotate the arm outward so that the thumb points away from the body

Extension – When a joint is held straight out (opposite of flexion)

Flexion – When a joint is bent (opposite of extension)

Nerve damage duration: Times involved are hard to estimate, but will partly depend on the spread of focussing of the compression, the weight of the person suspended, and the concurrent presence of blood vessel compression. Be aware that serious nerve damage can happen very quickly and often without warning. Consider this before you experiment with suspension or tight bondage.

Short term compression - tingling and loss of sensation.

Longer term (minutes) - loss of motor function (neuropraxia).

Longer still - longer recovery time.

Even longer - possibility of permanent injury (neurotemsis)

Recovery time depends a lot on how badly the nerve is damaged. It may just take a very short time if the nerve is mildly compressed. However, if the structure of the nerve is damaged, it can take week or months. A nerve is made up of thousands of nerve fibres held together in a bundle. Each fibre that has been disrupted will die back along its track to where the body of the cell is located which is right back to the spinal cord. It can regrow from there usually at a rate of about a millimetre a day. If the nerve sheath is not disrupted, then the individual nerve fibres should be able to find their way back to the sensory or muscle ending that they were originally connected to. In severe cases, surgery might be required to regain use.

A sketch of a dissected body, showing the nerves of the hand, can be found [here](#) in Gray's Anatomy, however Figs 1 and 3 show the information photographically. Starting at the wrists, you have three main nerves: ulnar (little finger side), median and radial (thumb side). The median isn't easily compressed by ropes, even under suspension as it lies deep within the carpal tunnel running up the middle of the wrist. People with Carpal Tunnel Syndrome are probably the exceptions as fibrous tissue fills the tunnel and leaves less room for the nerve.

The real problems are the other two nerves, radial and ulnar. Avoid the notch at the base of the thumb (Point A) and the notch you'll feel just at the end of the ulnar bone where the forearm ends and the hand starts (Point B), see Fig 1. At both these points the nerves are running near the surface over bony prominences, making the nerve compressible by overly tight or thin, i.e. narrow diameter rope or insufficient wraps, wrist bindings cutting into this area.

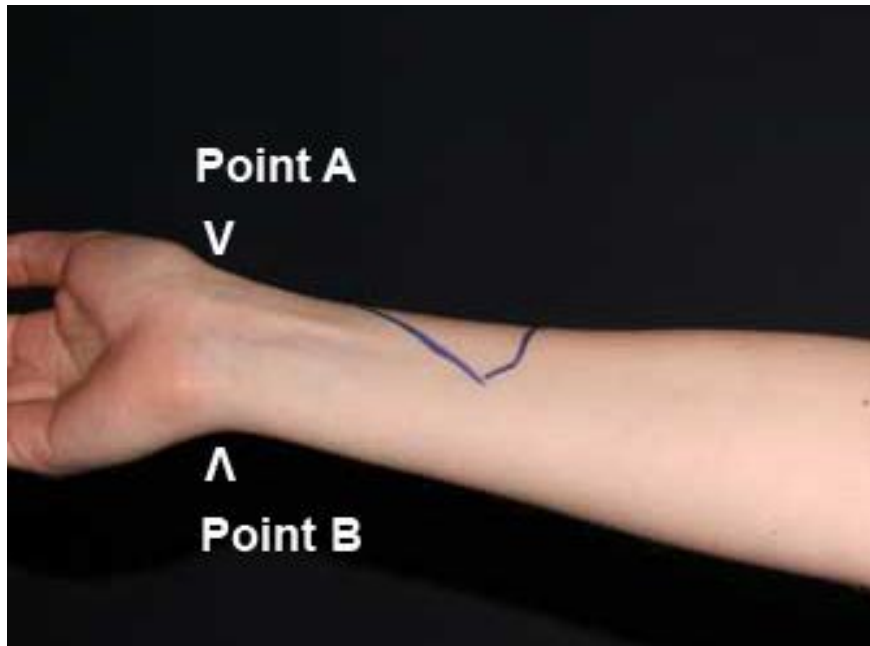


Fig 1. Showing vulnerable points on wrist

A sketch of a dissected body, showing the nerves of the arm, can be found [here](#) in Gray's Anatomy. See Fig 2 et seq. Moving up the arm, avoid the "funny bone", aka humerus, where the ulnar nerve runs over the bony prominences of the ends of the humerus and top end of the ulna. Compressing here gives similar symptoms to whacking it (the "funny bone") i.e. tingling in the inner (little finger) half of the hand (see Fig 1b), and importantly with time and degree of injury also leads to weakness in the fingers and both loss of grip strength and precision. Injuries to the ulnar nerve may also occur if the arm is very tightly bent (>90 degrees) at the elbow for prolonged periods; if the arm is twisted inward so the thumb faces the body tension on the ulnar nerve is further increased (think of the way you hold your arm while imitating a chicken wing or as in a wrist to upper arm tie).

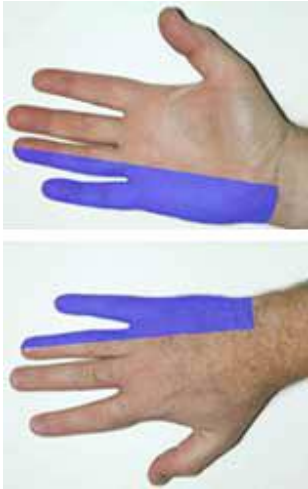

Fig 1b. Blue areas are served by ulnar nerve

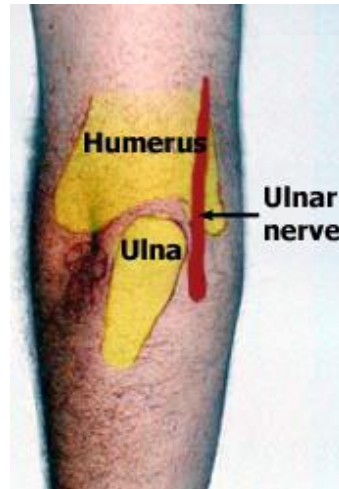


Fig 1c. Location of ulnar at elbow

Symptoms of ulnar nerve injury:

- Abnormal sensations in the 4th or 5th fingers
- Numbness, decreased sensation
- Tingling, burning sensation
- Pain
- Weakness of the hand

Again, the median nerve, in the middle of the front of the elbow is difficult to compress, as it's deep and surrounded by soft tissue, but with enough pressure the radial artery can be compressed, leaving the lower arm short of blood & oxygen. This point is just proximal to the bony parts of the wrist with the hand supine, where the pulse is normally taken. This remains vulnerable in a straight line up to about half way to the elbow, at which point the increased muscle bulk around the deeper running artery will be protective. This is both painful in itself, and after a few minutes can start to cause early tissue damage. Releasing the pressure the causes more pain as the blood supply returns.

Avoid the back/inner upper humerus (2-3 inches below the armpit) as the lower branches of the brachial plexus are compressed against the bone of the upper arm here, this time including the median nerve (causing major functional problems for the elbow and hand).

The radial nerve: is vulnerable at the wrist as mentioned above. In addition, it is also prone to injury where it twists around the outside of the arm between the

deltoid and triceps, see Figs 2 and 5. It is at its most exposed in the 'valley' between these two muscles. Since it is included in the brachial plexus, compression in this area can occur. A branch of the radial nerve near the lateral and posterior portion of the wrist does run close to the skin surface, see Fig 3, and tight ties in this region may lead to numbness along the back of the hand.

Symptoms of radial nerve injury:

Symptoms can affect the following:

- The hand or forearm (dorsal surface, the "back" of the hand)

- The "thumb side" (radial surface) of the dorsal hand

- The fingers nearest the thumb (2nd and 3rd)

The following symptoms may occur:

- Numbness, decreased sensation, tingling, or burning sensation

- Pain

- Abnormal sensations

- Difficulty extending the arm at the elbow

- Difficulty extending the wrist

Brachial plexus: In the armpit, all the major nerves to the upper limb are branching after emerging from the neck and upper thoracic spine, see Figs 3 and 4. They pass through the soft tissues beneath the shoulder joint. This is pretty well protected from above by the joint itself, behind by deltoid and trapezius, and from the front by the pectorals. Underneath, though, these nerves are vulnerable. Restraints should never be placed around the armpit as this will almost certainly lead to compression of all of the nerves that supply the arm. It's not just compression, but also excessive stretching, which can happen if the body is suspended with arms above the head. This is also a risk if the arms are pulled behind the back, when the head is turned to the opposite side, and when there is downward pressure on the shoulder. Obviously, the risk, and speed of onset of any injury, is greater in those who weigh more.

While certain scenes may require positioning that puts stretch tension on the brachial plexus, moving the person in bondage to the position slowly and steadily (without sudden movements) and minimizing the aforementioned pressures may help make arm restraint safer.

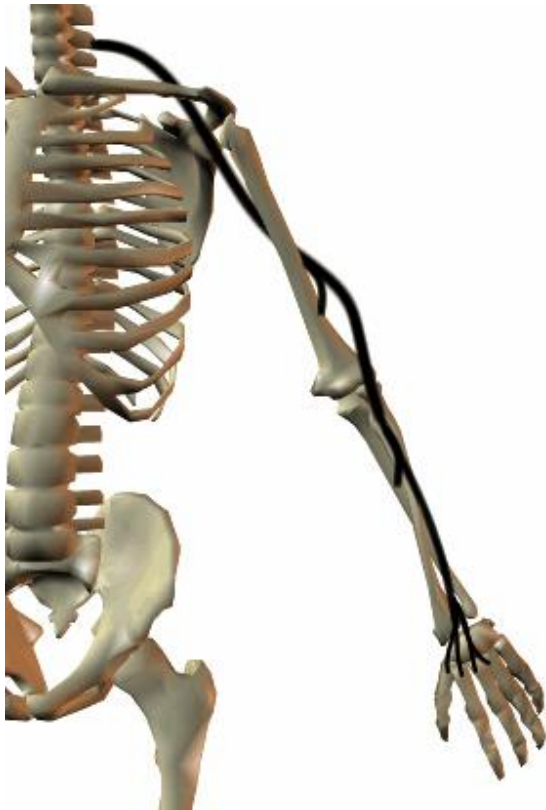


Fig 2. Diagram shows path of radial nerve. See [here](#) for anatomical version in Gray's Anatomy.

The illustrations show the main points where nerves are likely to be vulnerable. This is only a guide as anatomy varies and nerves will move according to position. The markings enclose the areas which should be treated with caution.

However, while nerve damage to the areas discussed may appear to be the source of change in sensation, in fact there are times that the pain is actually the result of compression of the nerve points around the vertebra. For instance, suspension with the head in a plane that might deform the natural position of the vertebrae; thus, pinching the nerves coming out at the vertebra. This situation is very highly probable in horizontal suspension when the head is unsupported. Often the sensation of pain from the cervical pain is manifested at a distance from the vertebra and could include sensation along the radial nerve right to the finger tips.

There are many variables, knock-on effects and bio-mechanical issues; there is no magic formula which avoids all risks. Furthermore, there is no medical specialisation in bondage related injuries, so creating this expertise is down to us.

In spite of all the best care and knowledge, shit happens. All we can do is be aware of the risks and how to minimise them.

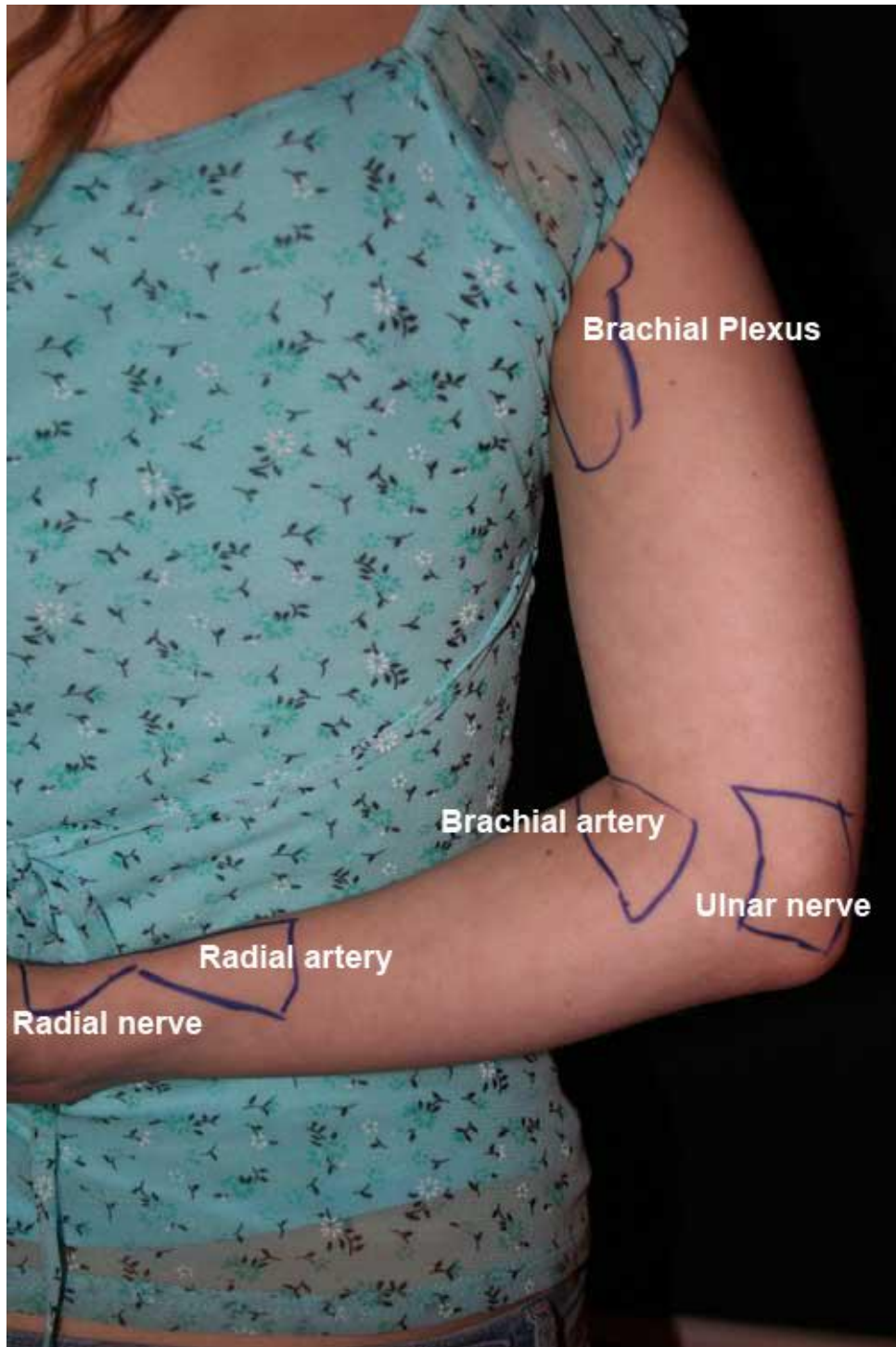


Fig 3. View from rear with arm in typical position

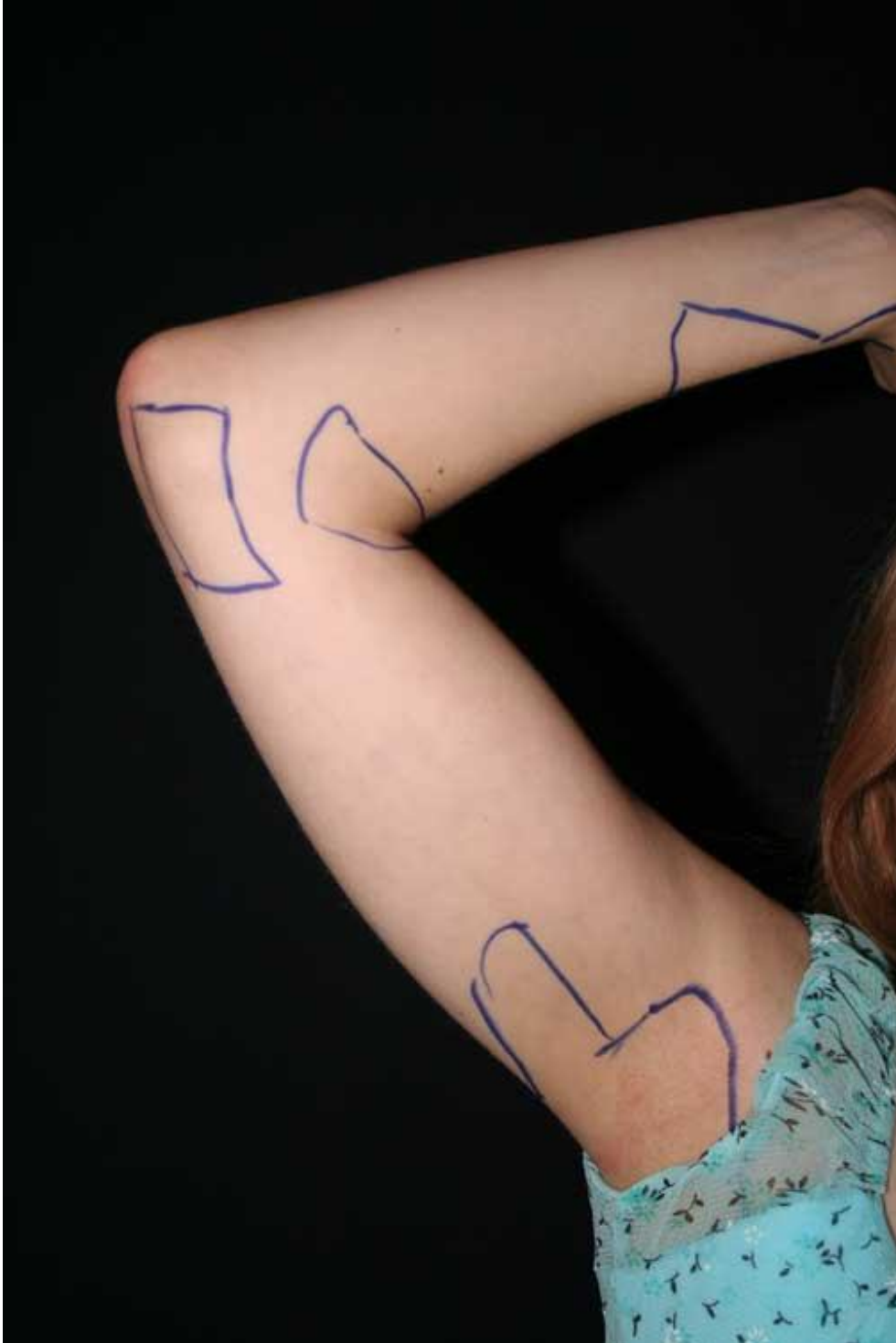


Fig 4. View from front, arm lifted to show brachial plexus in armpit.

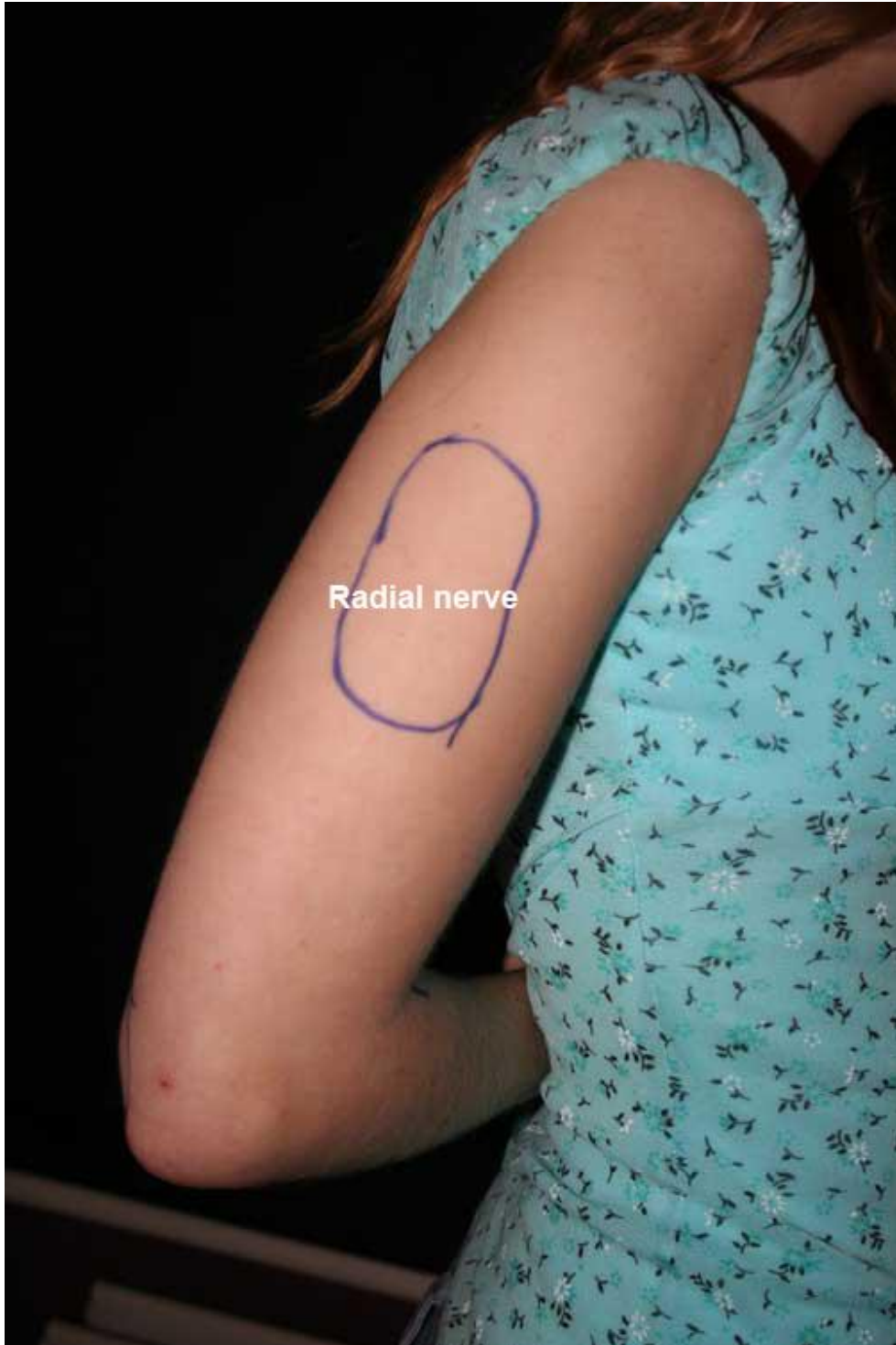


Fig 5. View from side with arm in typical position showing radial nerve

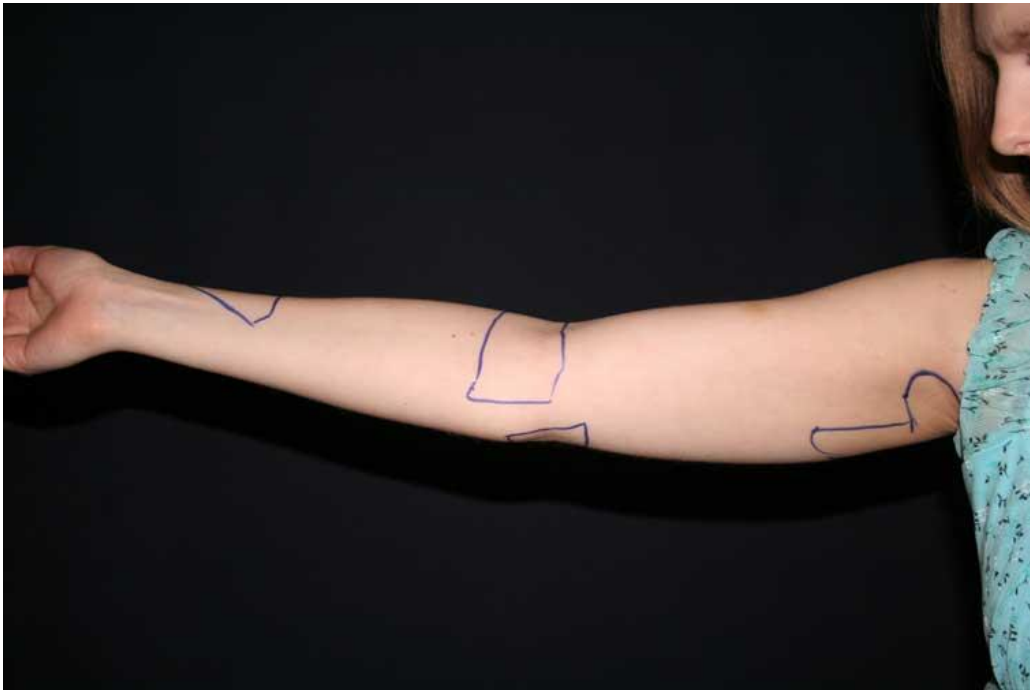


Fig 6. View from front, arm lifted to show brachial plexus in armpit.

The following illustrations show a typical takate-kote.

As can be seen from the following two illustrations, the bindings largely avoid the area on the outer arm, although the upper binding does clip the top edge. Some riggers place the lower binding higher than I have done. The marked area should be considered vulnerable. Attention should be paid to the risk of either of these bindings slipping into this area when under load.

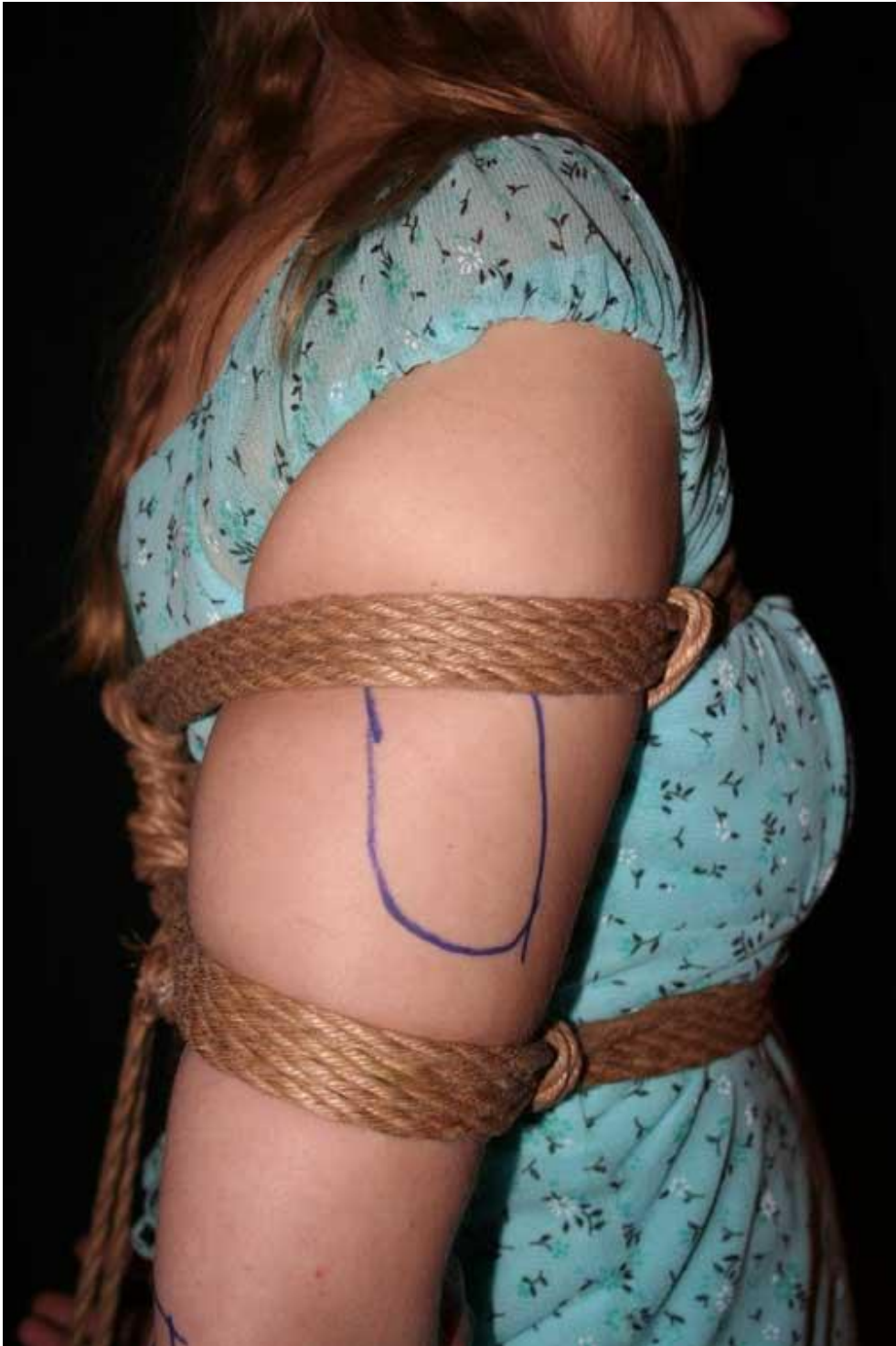


Fig 7.

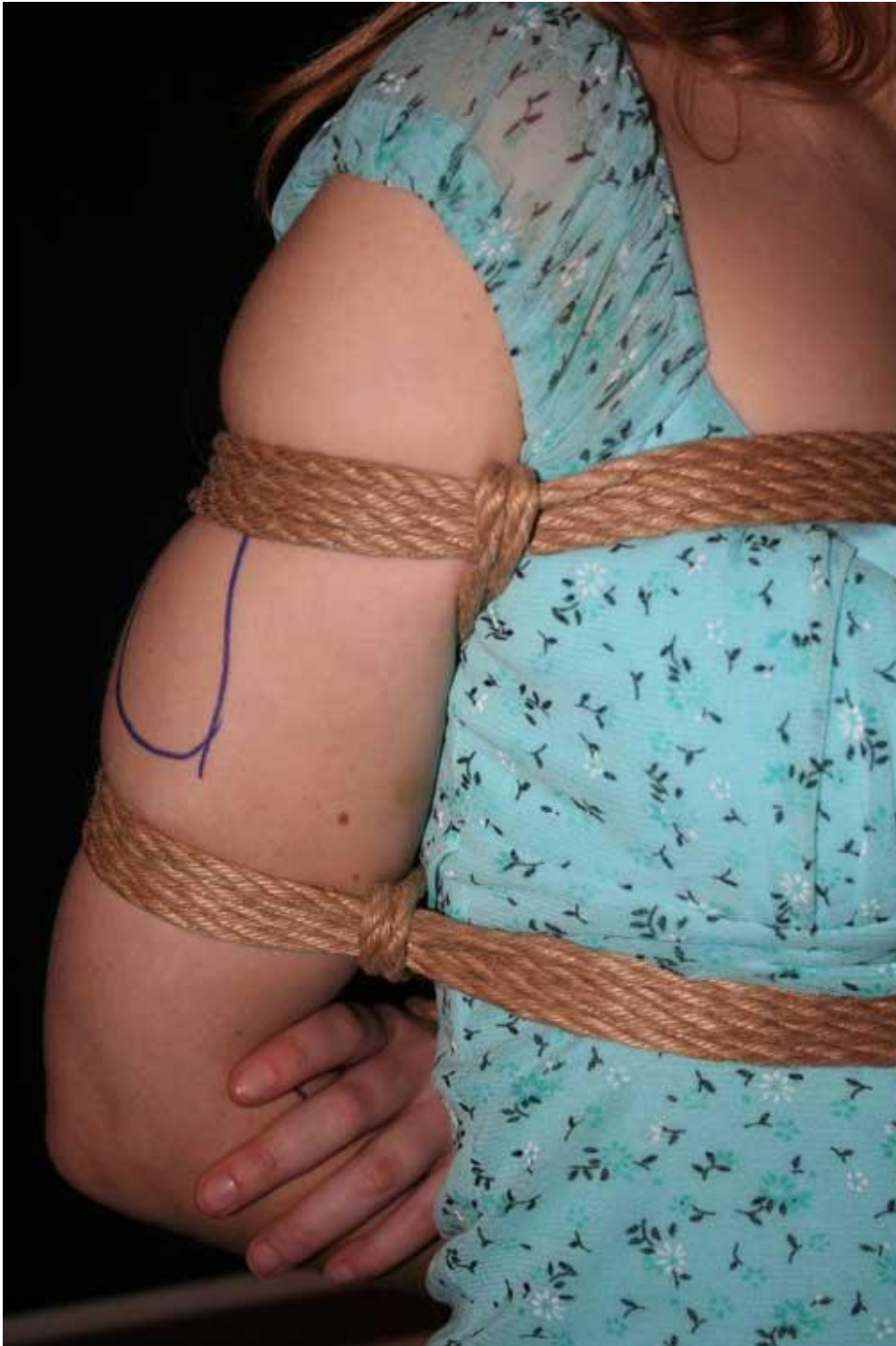

Fig 8.

Due to the reluctance of people to discuss their experiences, I have little to go on beyond the 'grapevine' and a few individual reports. However, I have noted a preponderance of injuries, usually affecting the radial nerve, and often relating to sideways suspension. In the latter, the tendency is for this to affect the lower arm (nearest the ground), which will be under the greater load. I would like to speculate upon some causes, apart from incorrect construction:

1. The upper binding moving into the danger area (shown above).
2. Failure to run a finger under the upper binding to allow underlying tissue to 'settle'. This ensures nerves are not trapped by muscle and return to their normal position in the protective groove.
3. The cinch rope on the upper binding being pressed into the lower end of the brachial plexus. I believe that this nerve bundle could be pinched between rope, ribs and arm bone. This being a possibility, I would question the wisdom of the upper cinch when using this tie for sideways suspension.

Apart from the above, I do not see any problems with the arm/body portion of this tie, when correctly applied. All the other problem areas are well away from the components.

However, the position of the hands needs to be watched. It is common for the model to change hand position significantly during a suspension. Even if wrists are placed against each other to protect the sensitive inner sides, they can be rotated. I have often seen an attempt to straighten the arms leading to them ending up in an 'X' position. As can be seen below, the radial artery on the thumb side of the wrist is in risk of pressure. 'Scissoring' of the arms can also increase the tension further. These are all good reasons to ensure sufficient slack in the wrist tie. After all, it is the restriction of the arms, not the wrist tie, which provides most of the immobilisation. Keep an eye out for over-tightness and the consequent signs of discomfort, e.g. flexing fingers, discolouration.



*With thanks to: Vitimin A, Sluttylatexboy for their medical input and those who have shared their experiences.*

*Please email me with any comments or additions: [bruce@esinem.com](mailto:bruce@esinem.com)*

*Please circulate this information freely. However, it would be courteous to include a credit and link to [www.esinem.com](http://www.esinem.com). More safety information can be found on my site: [www.esinem.com](http://www.esinem.com)*